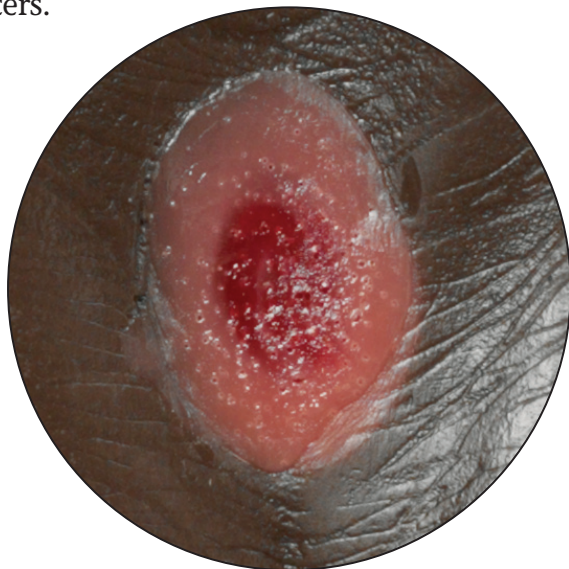
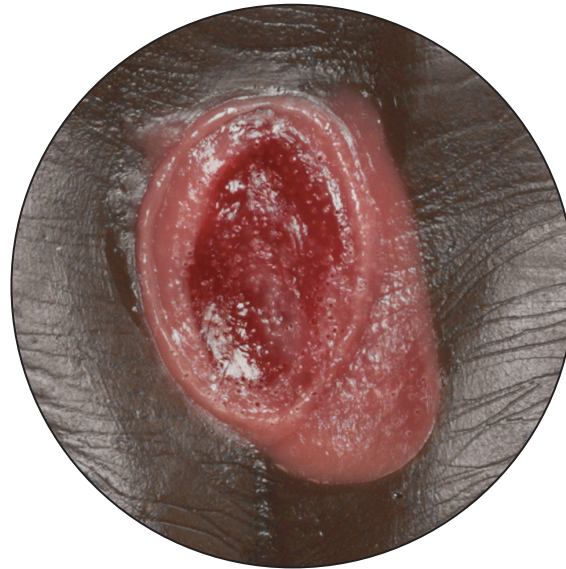
Pressure ulcers, also known as bedsores or decubitus wounds, affect over one million adults every year. The wounds can range from superficial and mildly red on the skin surface to a deep open wound penetrating down to the bone with blackened or dead tissue and extreme infection. The **Life/form**[®] Pressure Ulcer Models are a set of four models that show all four wound stages. Use these models to teach the various stages or give instruction on the care and cleaning of the ulcers.



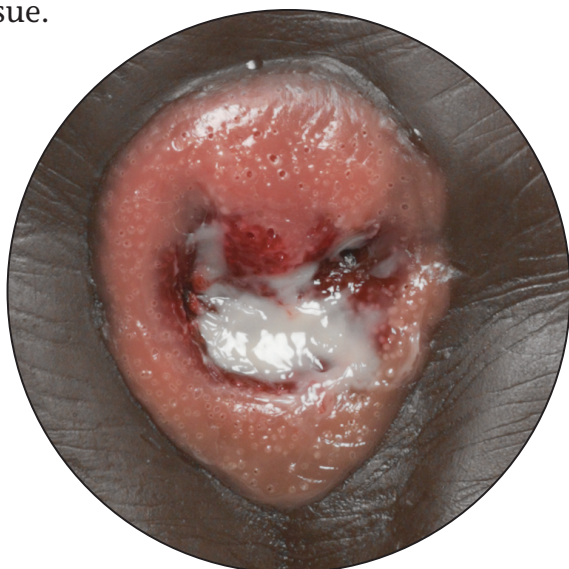
STAGE 1

Intact skin with non-blanchable redness, usually over a bony prominence. A patient may feel the area is painful, firm, soft, warmer, or cooler as compared to other skin tissue.



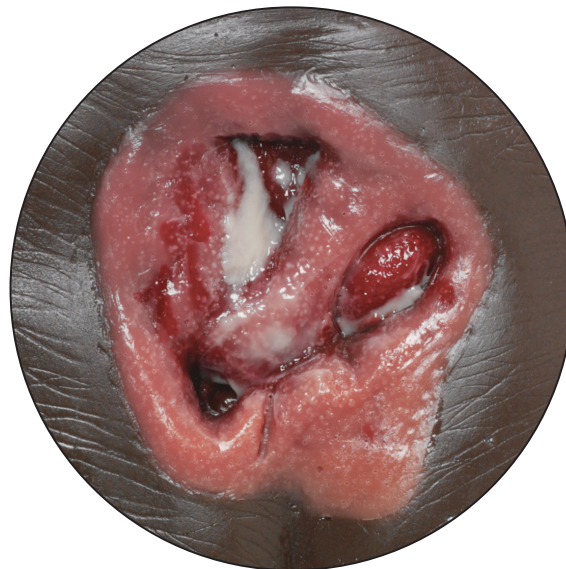
STAGE 2

Open wound that is reddening with partial skin loss of dermis presenting a shallow open ulcer with a red-pink wound bed.



STAGE 3

Deep open wound that reaches through all layers of skin and into the muscle. Full thickness tissue loss. Subcutaneous fat may be visible but bone, tendon, and muscle are not exposed.



STAGE 4

Severe, deep open wound that reaches through all layers of skin and damages muscle, bone, tendons, and joints. Slough or eschar may be present on some parts. Often includes tunneling.